

CASE REPORTS

Congenital Diaphragmatic hernia presenting in adult life: A study of two cases

Amaratunga HA¹, Peiris SPM², Lamawanse MD²

¹*Department of Anatomy, Faculty of Medicine, University of Peradeniya, Peradeniya, Sri Lanka*

²*Department of Surgery, Faculty of Medicine, University of Peradeniya, Peradeniya, Sri Lanka*

Running title: congenital diaphragmatic hernia diagnosed in adults

Abstract

Congenital Diaphragmatic hernia (CDH) usually presents in the newborn and rarely present as undetected cases in adult life. Defects in the diaphragm can cause abdominal organs to herniate into the thoracic cavity resulting in respiratory distress or strangulation of abdominal organs. Reported here are 3 cases of congenital CDH presenting in adult life.

A 59-year-old male presenting with epigastric pain, bilious vomiting and constipation demonstrated an air-fluid level in the anterior mediastinum on chest radiograph. Surgery revealed an anterior Morgagni defect with a loop of terminal ileum herniated and strangulated into the pericardial sac.

A 15-year-old girl presenting with abdominal pain and pyrexia for 2 days, on CT chest and abdomen revealed right lobe of liver and transverse colon in the right hemithorax with the pericardium pushed to the opposite side. Surgery revealed a large right sided Bochdelaks type hernia. A strangulated gangrenous transverse colon was removed from within the thoracic cavity.

In these cases the body had adapted by maintaining total lung volume by compensatory hyperplasia of the contralateral lung allowing the patients to survive with no symptoms for a long duration of time. Even though rare, the possibility of CDH presenting as acute abdomen is important to remember.

Key words: congenital diaphragmatic hernia, bowel loops in the thorax, fluid levels in thorax

Introduction

Congenital diaphragmatic herniae (CDH) are a relatively rare group of disorders occurring in 1-5: 10000 births¹. CDH is usually diagnosed soon after birth or during childhood mostly because its association with lung hypoplasia which leading to dyspnoea early in life. However cases have been reported where patients have lived with such defects without any complications to adult life^{2,3}. Here we report the clinical findings and outcomes in two such cases of CHD which survived to adult life undiagnosed.

The diaphragm develops from four main structures: septum transversum, pleuroperitoneal membrane, dorsal

oesophageal mesentery and the body wall. The final closure of these parts occurs at 8 to 10 weeks of gestation at the Bochdaleks foramen. Defective closure allows abdominal organs to herniate into the developing thoracic cavity compressing and causing malformation of the lungs and sometimes the heart. Lung hypoplasia is a common associated defect. Left sided defects are commoner with the liver being protective and preventing right sided ones. Anterior defects are through the Morgagni's foramen, between the diaphragm and sternum.

Etiology of CHD is multifactorial with a majority of cases being syndromic. However isolated cases of CHD which are non-syndromic are reported. Less than 2% are familial with autosomal and X-linked varieties being reported.

Three basic types of CDH are described: the posterolateral Bochdalek hernia, the anterior Morgagni hernia, and the hiatus hernia. The Bochdalek hernia occurs in approximately 85% of cases. Left-sided hernias allow herniation of both the small and large bowel and intra-abdominal organs into the thoracic cavity. In right-sided hernias which account for 13% of cases, the liver and parts of the colon herniate into the thoracic cavity.

Case 1

A 59 year old male was admitted to the surgical casualty with burning epigastric pain and bilious vomiting that had developed over the preceding 4 hours. He had not opened bowel for three days. On examination he had a distended abdomen. A diagnosis of acute

intestinal obstruction was made. Postero-anterior and lateral chest radiographs demonstrated an air-fluid level in the anterior mediastinum (Figure 1). The patient rapidly became septic despite nasogastric decompression and intravenous fluid therapy. An urgent exploratory laparotomy was performed, which revealed an anterior Morgagni defect in the diaphragm through which a loop of terminal ileum had herniated to lie within the pericardial sac. The sharp edge of the diaphragmatic defect was seen to have strangulated the intestinal loop. The loop of affected bowel and the ischaemic tuft of omentum were resected and a double barrel ileostomy was exteriorised in the right iliac fossa. The diaphragmatic defect was repaired in two layers using an interrupted non-absorbable suture. The patient made an uneventful recovery and underwent reversal of ileostomy eight weeks later.

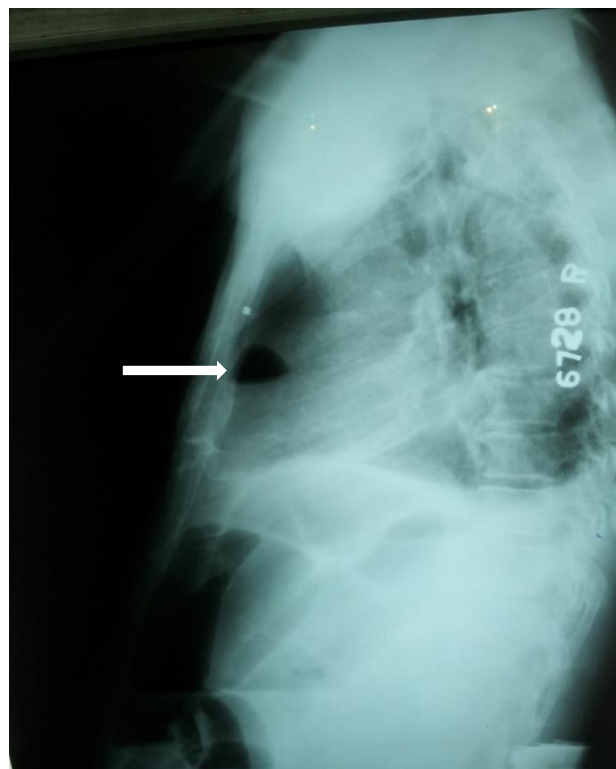


Figure 1: air fluid level in lateral chest radiograph

Case 2

A 15 year old girl presented to surgical casualty with severe abdominal pain and difficulty in breathing that had developed rapidly over the preceding 8 Hrs. She had been having on-off abdominal pain related to meals over the past several years. Previously she had been investigated for eventration of the right hemidiaphragm in a specialist thoracic unit conservatively. On admission she was ill febrile tachycardic and tachypnoic. Right sided air entry was reduced and percussion note dull. The abdomen was soft and non-tender. Chest X ray PA revealed a large loop of large bowel in the right hemithorax and a diffuse opacity in the right lower zone (Figure 2). CT scan confirmed the presence of bowel in the right hemithorax and the lower zone opacity was found to be the right hemi liver (Figure 3).

Following resuscitation, emergency laparotomy was performed. A modified

rooftop incision was employed to gain access to the upper abdomen. A Bochdalek type posterior defect was found in the right hemidiaphragm. Through this defect the right hemi liver had herniated into the right hemithorax along with the entire transverse colon, which was gangrenous. The right hemiliver was adapted to fit the cavity of the right hemithorax indicating that this anatomy may have been present for a long time. The diaphragmatic defect was enlarged. The right hemi-liver was delivered into the abdomen after division of its anchoring ligaments whilst safeguarding the vascular architecture. The gangrenous loop of bowel was delivered to the abdomen and excised. The diaphragm was repaired in 2 layers. The presence of the large right hemi-liver precluded any attempt at abdominal closure. Following a temporary closure the patient made a gradual recovery.

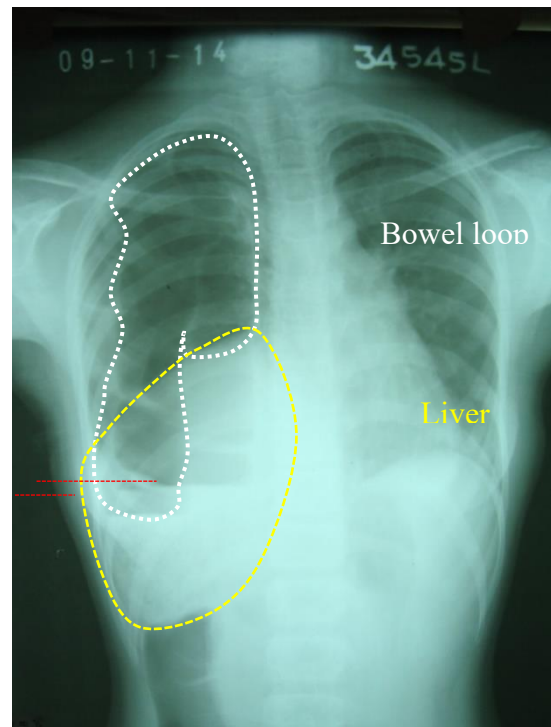
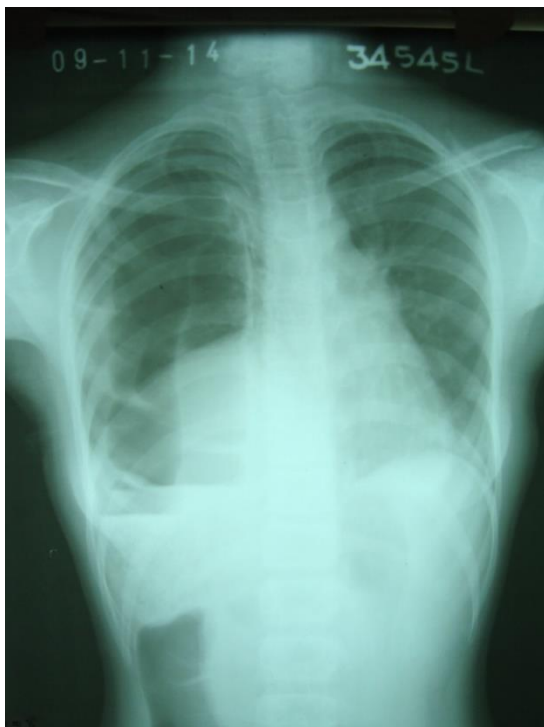

Figure 2: Antero-posterior chest radiograph showing bowel loop (white) with fluid levels (red) and the right hemi liver (yellow) in the right hemithorax

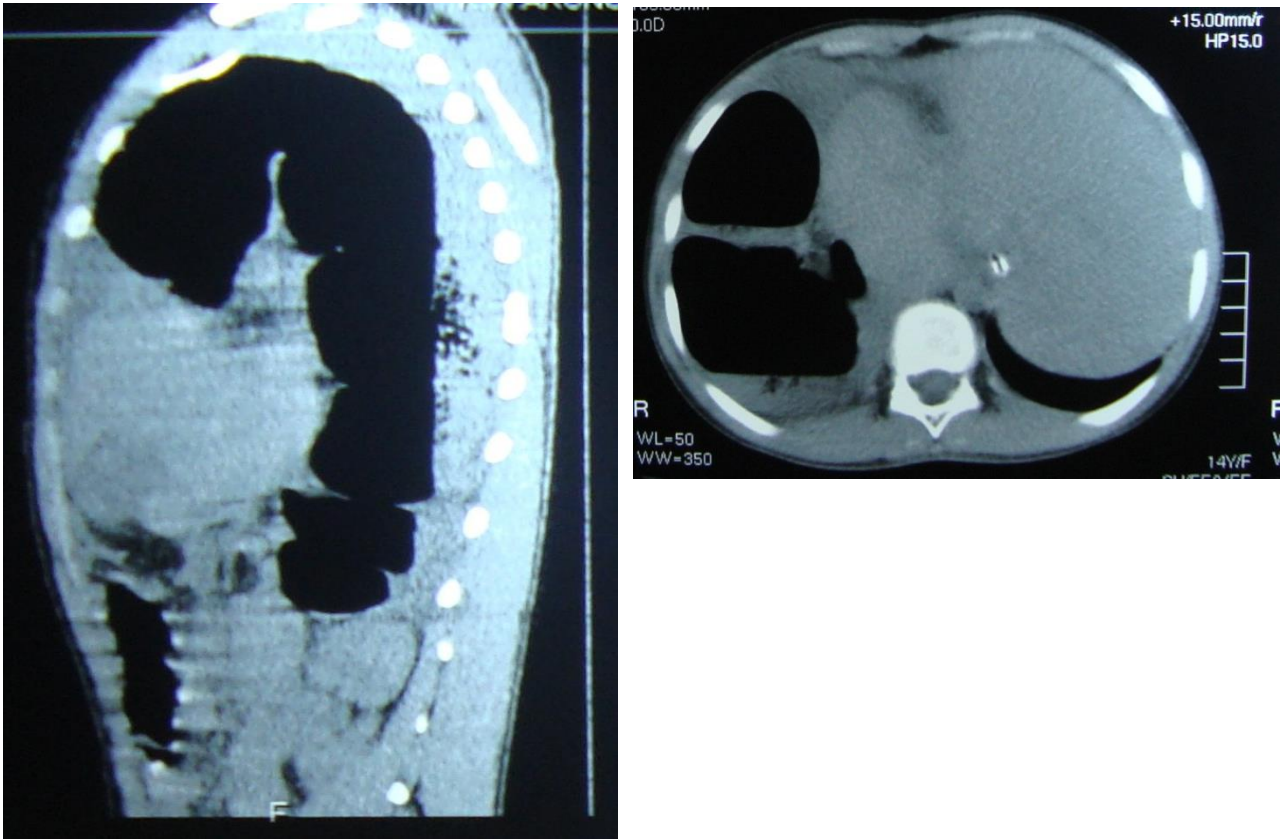


Figure 3: Axial and sagittal CT abdomen showing the bowel loop in the thorax

Discussion

CHD tends to be diagnosed at birth or infancy due to features related to lung hypoplasia and other congenital defects. However isolated CHD may go undiagnosed in rare cases with the patients surviving into adulthood with minimal or no symptoms. In the two cases discussed here one patient had gone undiagnosed till the age of 59 and the other until 14 years.

In the first case an anterior Morgagni's diaphragmatic hernia has caused loops of small intestine to herniate into the thoracic cavity giving rise to intestinal obstruction. Morgagni's defect is a congenital defect in the anterior diaphragm due to incomplete fusing of

the septum transversum with the sternum and/or ribs. Giovanni-Battista Morgagni first described this type of hernia in 1761⁴. This type of CDH represents approximately 1-3% of surgically treated diaphragmatic hernias⁵. This defect may go unnoticed or cause respiratory distress in infancy or as reported here features of strangulated bowel in adulthood. Small bowel and omentum being the most mobile parts of the gut have a chance of herniating through such defects. Herniation of the terminal ileum into the thorax is extremely rare. The presence of an air fluid level denoting bowel in the anterior mediastinum is highlighted as a rare finding on chest radiography.

In the second case which was a Bochdalek type hernia where the liver and the small bowel had herniated into the thorax, the body had adapted by maintaining total lung volume by compensatory hyperplasia of the contralateral lung. Bochdalek hernia occurs due to incomplete fusion of the pleuroperitoneal membrane posterolaterally. This type of hernia is invariably diagnosed at birth or infancy due to respiratory symptoms. Since the left side of the pleuroperitoneal membrane closes last left sided defects are commoner. However in the case described here the defect was right sided and was diagnosed at the age of 15 years. It was fascinating to find the liver molded to the shape of the thoracic cavity. It appeared that the herniation of bowel loops had occurred as an acute event giving rise to symptoms.

Even though rare, the possibility of CDH presenting as acute abdomen in later life is important to remember.

Acknowledgement

None

Conflict of interest

None

Corresponding author

Dr. (Mrs.) H.A. Amaratunga,
Department of Anatomy,
Faculty of Medicine,
University of Peradeniya,
Peradeniya, 20400, Sri Lanka.

Email: himanipeiris@yahoo.com,
himanip@pdn.ac.lk

Tel: +94 81 2396275

Fax: +94 81 2389106

CC BY 4.0

This is an Open Access article distributed under the terms of the Creative Commons Attribution 4.0 license (unless stated otherwise) which permits unrestricted use, distribution and reproduction in any medium, provided the original work is properly cited. Copyright is retained by the author(s).

References

1. Gallot D, Boda C. Prenatal detection and outcome of congenital diaphragmatic hernia: a French registry-based study. *Ultrasound Obstet Gynecol.* 2007; 29(3): 276-283.
2. Marichez A, Fernandez B, Chiche L. Bochdalek diaphragmatic hernia with bowel incarceration. *J Visc Surg.* 2020; <https://doi.org/10.1016/j.jviscsurg.2020.11.005>.
3. Jandus P, Savioz D, Purek L, Frey JG, Schnyder JM, Tschopp JM. Bochdalek hernia: a rare cause of dyspnea and abdominal pain in adults. *Rev Med Suisse.* 2009; 5(203):1061-1064.
4. Morgagni GB. In: Millar A, Cardell T. eds. *Seats and Causes of Diseases.* Vol. London:1769:205
5. Comer TP, Clagett OT. Surgical treatment of hernia of the foramen of Morgagni. *J Thorac Cardiovasc Surg.* 1966 Oct; 52(4):461-8.