

BRIEF COMMUNICATION

Morphometric evaluation and quantification using Fiji

Mathangasinghe Y¹, Samaranyake UMJE²

¹*Department of Anatomy, Faculty of Medicine, University of Colombo, Colombo, Sri Lanka*

²*Department of Anatomy, Faculty of Medicine, Sabaragamuwa University of Sri Lanka*

Abstract

Fiji is a free software which can be used for image analysis in anatomical studies which allows obtaining accurate measurements of fine structures for morphometric evaluation. Fiji has a user-friendly interface with no requirement of programming skills, hence it has gained a wide interest among basic scientists. Here, we describe a protocol for obtaining basic measurements in gross anatomical and radiological studies using Fiji.

Key words: Fiji, ImageJ, quantification, measurements, anatomy

Article

Introduction

A myriad of studies in gross anatomy, radiological anatomy and developmental biology utilize measurements such as distance, angle, area, volume and curvature to describe morphology of different structures. The classical approach of obtaining these measurements was to use instruments such as calipers (1), measuring tapes (2), set squares (3) and goniometers (4). Often magnifying glasses were used to aid measurements since fine structures could not be accurately resolved

by the naked eye (5). This approach had several limitations when measuring curvilinear distances, angles and areas which necessitated indirect measuring strategies such as using threads (3). Moreover, since the measurements were obtained real-time, it was laborious to revisit the specimens and obtain new measurements for subsequent analyses and revisions of the studies.

These shortcomings could be easily overcome by utilizing image analysis software for morphometric evaluation in anatomical studies. Fiji (previously known as ImageJ) is one such popular software used by the basic scientists worldwide for image analysis. Fiji was originally developed by the National Institute of Health (NIH) for analysis of histological images (6). It is an open source (free) software which is constantly being modified and enhanced by the users and universally accepted by high impact journals inclusive of Nature, Cell and Science (6). Fiji has a user-friendly interface with no need of knowledge in programming languages and coding. It allows obtaining a wide array of measurements to analyze structural morphology encompassing linear and curvilinear distances (7), angles (7), area (8), and volume (9). Measurements can be obtained accurately after magnifying images (10) which increases reproducibility. Large

scale image analyses such as detection and counting of vascular (11) and neural (12) networks can be conducted using automated 'macros' and freely available extensions of Fiji. Moreover, there is a growing interest in analyzing 3-dimensional datasets based on cadaveric and radiological cross-sections, which could be easily achieved by using this software (10, 13).

The objective of this paper is to introduce Fiji for anatomical and radiological studies. Here, we describe a protocol for obtaining basic measurements such as distance, angle and area.

Protocol

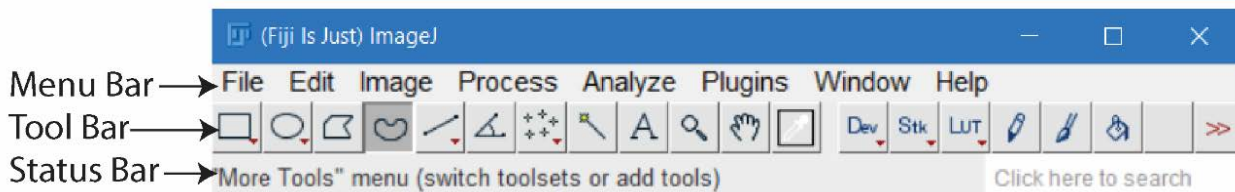
Setting up Fiji environment

Fiji can be downloaded from the site (<https://imagej.net/Fiji/Downloads>). Once extracted, Fiji can be launched by clicking on the Fiji/ImageJ.exe icon. Figure 1 shows the Fiji interface. The software can be updated by selecting Help → Update.

Getting sources of data

The structures which need to be measured are required to be photographed with a scale (ruler or a caliper) kept at the same plane of the specimen (Figure 2A). Having a fixed distance between the camera and the specimen will make image analysis faster. Care should be taken to orient the specimen perpendicular to the camera lens.

A)



B)

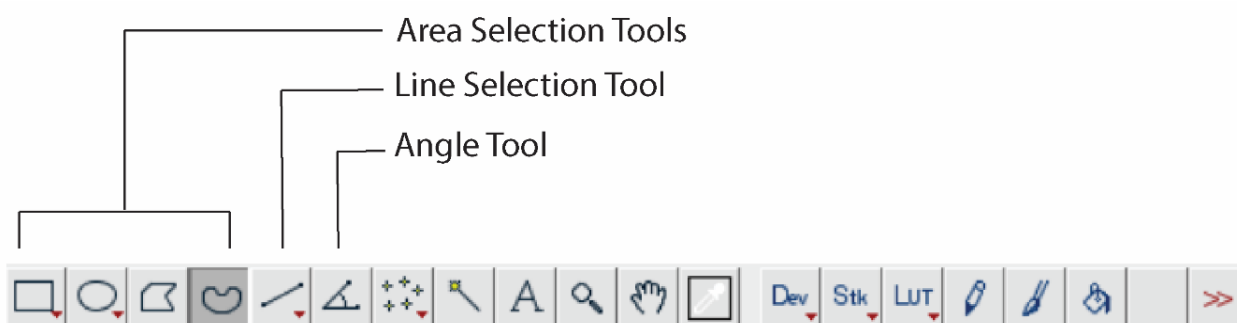


Figure 1: Fiji interface. A) Menu Bar, Tool Bar and the Status Bar of Fiji. B) Inset of Tool Bar showing tools that are used for various measurements.


Importing images to Fiji

Fiji supports a variety of file formats inclusive of JPEG, PNG, GIF, TIFF, BMP, DICOM. They can be imported by selecting File → Open. Alternatively, the images can be dragged and dropped on to the interface.

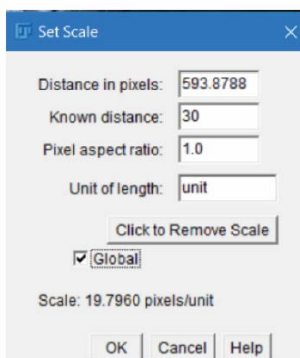
Calibration

If the images have been obtained at a fixed distance, the images can be calibrated to obtain the subsequent measurements. First, a line should be drawn across the scale (Figure 2A) using the Line Selection tool (Figure 1B). Then the scale should be set up by selecting Analyze → Set Scale. In the dialog box (Figure 2B) the “known distance” should be entered. The calibration is applied to all the opened images if the “global” option is selected. The settings can be applied by clicking OK.

A)



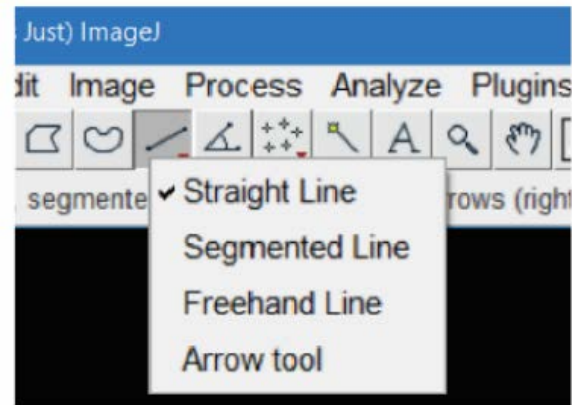
B)



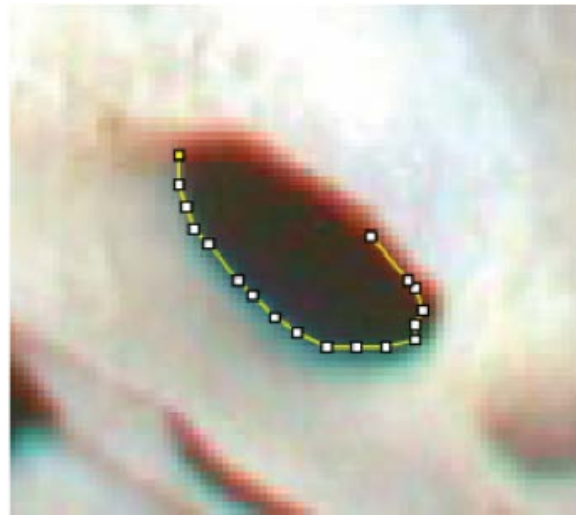
C)

	Area	Mean	Angle	IntDen	RawIntDen	Length
1	0.885	90.286	30.793	79.946	31329.183	17.465

D)



E)



F)

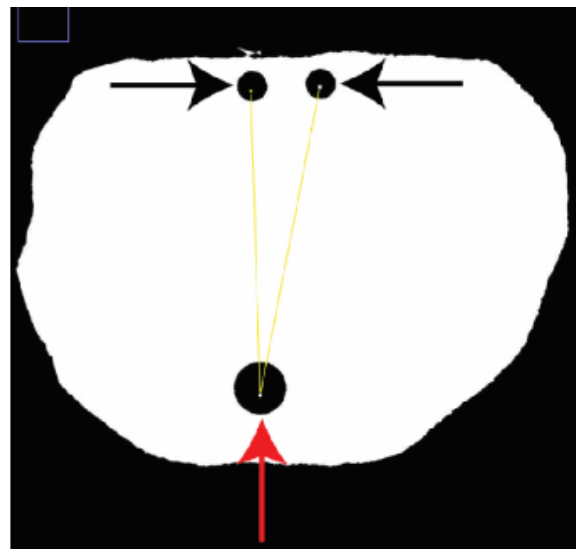


Figure 2: Image analysis using Fiji. A) Calibration of the images. The arrow indicates the line drawn on the ruler to set the scale. **B)** Dialog box for setting scale. **C)** Output of the measurements. **D)** Different line selection tools. **E)** Measuring the circumference of the foramen ovale of the skull using the Segmented Line tool. **F)** Measuring the angle between two ejaculatory ducts (black arrowheads) relative to the prostatic urethra (red arrowhead) on a cross section of the human prostate using Angle tool.

Obtaining measurements

Distance – linear and curvilinear

Once the scales are set (see under calibration), the distances can be measured by drawing a line between the structures of interest using the Line Selection tool (Figure 1B). The actual distance is now displayed in the status bar as the “length”. The measurement can also be obtained by clicking Analyze → Measure (or Ctrl+M) and scrolling to the “length” tab (Figure 2C), which can be subsequently copied to a database (eg: Excel, SPSS). The curvilinear distances can be measured in a similar way using the “segmented line selection” tool (Figures 2D and 2E). The segmented line tool can be selected by right clicking on the line selection tool and selecting the segmented line option (Figure 2D).

Angle

Angle tool (Figure 1B) is used for measuring angles. The intended angle needs to be indicated by selecting three points (Figure 2F).

The measurement can be obtained by clicking Analyze → Measure, and scrolling to the “angle” tab.

Area

The region of the structure can be first selected using area selection tools (Figure 1B). The measurement can subsequently be obtained by selecting Analyze □ Measure and scrolling to the “area” tab.

Advanced analyses and image editing

A variety of other measurements in biological image analysis such as curvature, skewness, kurtosis, center of mass, perimeter, shape descriptors can be obtained by Fiji, which is beyond the scope of this article. A scale bar can be added to the images using Fiji for publication purposes. Fiji also allows a variety of options for image editing such as sharpening, smoothening, contrast enhancement. However, care should be taken to apply the same parameters/modifications for the entire dataset in order to prevent “image manipulations”.

Conclusions

Fiji is an open source software which allows a variety of image analysis options for anatomical research which is widely accepted by the scientific community.

Acknowledgement

None

Conflict of interest

None

Corresponding author

Dr. Yasith Mathangasinghe (*MBBS*)

Lecturer,

Department of Anatomy,

Faculty of Medicine, University of Colombo,
25, Kynsey Road,

Colombo, Sri Lanka

Zip code: 00800

ORCID: 0000-0003-4641-5642

E-mail: yasith@anat.cmb.ac.lk

Tel: +61 41 0285497

CC BY 4.0

This is an Open Access article distributed under the terms of the Creative Commons Attribution 4.0 license (unless stated otherwise) which permits unrestricted use, distribution and reproduction in any medium, provided the original work is properly cited. Copyright is retained by the author(s).

References

1. Anthony DJ, Basnayake BMOD, Ganga NMG, Mathangasinghe Y, Malalasekera AP. An improved technical trick for identification of the thoracodorsal nerve during axillary clearance surgery: a cadaveric dissection study. Patient safety in surgery. 2018;12(1):18.
2. Mathangasinghe Y, Samaranyake U, Silva S, Prematilaka H, Perera M, Shantha S. Anatomical landmarks to locate the junction between transverse and sigmoid sinuses in translabyrinthine and retrosigmoid open surgical approaches. Sri Lanka Journal of Surgery. 2018;36(2).
3. Anthony DJ, Mathangasinghe Y, Samaranyake UM, Basnayake BM, Malalasekera AP. Pigmented border as a new surface landmark for digital nerve blocks: a cross sectional anatomical study. Journal of Hand Surgery (European Volume). 2019;44(9):932-936.
4. Raheem OA, O'Brien M. Anatomical review of the lateral collateral ligaments of the ankle: a cadaveric study. Anatomical science international. 2011;86(4):189-193.
5. Anthony DJ, Basnayake BMOD, Mathangasinghe Y, Malalasekera AP. Preserving the marginal mandibular branch of the facial nerve during submandibular region surgery: a cadaveric safety study. Patient safety in surgery. 2018;12(1):1-5.
6. Schneider CA, Rasband WS, Eliceiri KW. NIH Image to ImageJ: 25 years of image analysis. Nature methods. 2012;9(7):671-675.
7. Mathangasinghe Y, Samaranyake U, Maddumaarachchi H, Malalasekera A, Anthony D. Pigmented border of the toe as a consistent landmark to the digital nerve. Journal of Plastic, Reconstructive & Aesthetic Surgery. 2020.

8. Demir M, Atay E, Güneri B, et al. Morphometric Measurements of the Hip Bone in Turkish Adult Population. *Kobe J Med Sci.* 2018 Dec 10;64(4):E149-e156. eng. Epub 2019/02/08. Cited in: Pubmed; PMID 30728341.
9. Aceves GAG, López MAC, Vanegas MA, et al. Fractal anatomy of the hippocampal formation. *Surgical and Radiologic Anatomy.* 2018;40(11):1209-1215.
10. Malalasekera AP, Sivasuganthan K, Sarangan S, et al. Morphological variations of the human ejaculatory ducts in relation to the prostatic urethra. *Clinical Anatomy.* 2018;31(4):456-461.
11. Morin KT, Carlson PD, Tranquillo RT. Automated image analysis programs for the quantification of microvascular network characteristics. *Methods.* 2015;84:76-83.
12. Diz-Díaz J, Gómez-Muñoz E, Sañudo J, Marañillo E, Pascual-Font A, Vazquez T. Which is the function of a martin-gruber connection? *Clinical Anatomy.* 2019;32(4):501-508.
13. Doube M, Kłosowski MM, Arganda-Carreras I, et al. BoneJ: free and extensible bone image analysis in ImageJ. *Bone.* 2010;47(6):1076-1079.